

Communication

# Global Facial Rejuvenation Using a New Cohesive, Highly Concentrated Hyaluronic Acid Filler: A Descriptive Analysis of 35 Cases

Maria Claudia Almeida Issa <sup>1,\*</sup> , Andreia Fogaça <sup>2</sup>, Eliandre Palermo <sup>3</sup>, Luciana Maluf <sup>4</sup> , Patricia Ormiga <sup>5</sup>,  
Luciana Conrado <sup>6</sup> and Luis Henrique Barbizan de Moura <sup>7</sup>

<sup>1</sup> Department of Internal Medicine, Fluminense Federal University, Niteroi 24033-900, Brazil

<sup>2</sup> Independent Researcher, São Paulo 05414-901, Brazil; andreaia@andreaifogaca.com.br

<sup>3</sup> Independent Researcher, São Paulo 05455-001, Brazil; eliane.palermo@gmail.com

<sup>4</sup> Independent Researcher, São Paulo 04532-001, Brazil; lmaluf@hotmail.com

<sup>5</sup> Independent Researcher, Rio de Janeiro 22440-033, Brazil; paormiga@gmail.com

<sup>6</sup> Independent Researcher, São Paulo 04515-011, Brazil; luconrado@yahoo.com.br

<sup>7</sup> Department of Dermatology, Federal University of Sao Paulo, São Paulo 04039-001, Brazil; luishenriquemoura3@gmail.com

\* Correspondence: dr.mariaissa@gmail.com or mariaissa@id.uff.br; Tel.: +55-21-999815924

**Abstract:** Cosmetic procedures using fillers have gained importance over the last decades due to their ability to offer rejuvenation and beautification quickly with no (or minor) side effects. Hyaluronic acid (HA) gel is the most used filler in cosmetic dermatology; its physical and chemical properties vary according to the manufacturing process. The characteristics of the final product are crucial for its clinical indication. Specific physicochemical properties of HA gel are required to fill, volumize, sustain, and contour different anatomical areas and layers. Ideally, HA gels should have a consistency similar to that of the surrounding tissue to promote a natural feel, but, at the same time, they should be able to sustain their shape against constant physical strain caused by muscle contraction during mimic movements. Generally, softer gels are indicated to fill superficial layers, and are not usually meant to perform lifting or volumizing, for which stiffer gels are proposed. Therefore, combining gels with different characteristics is indicated for global facial treatment. The Brazilian market recently introduced a new Korean HA filler. Still, clinical evaluation of global facial treatment using these products is lacking in the literature. This study aims to describe clinical results, patient satisfaction, and side effects of facial treatment using these fillers. We analysed the clinical impact of global facial treatment in 35 patients performed by seven dermatologists. Patients of both sexes desiring beautification or rejuvenation were included, and all of them had indications for the filling procedure. Three Korean HA gels (e.p.t.q. S100, S300, and S500, Jetema<sup>®</sup>) with high HA concentrations and cohesiveness, varying only in their crosslinking degree, were used. The dermatologists chose the product for each procedure based on their rheological properties and clinical assessment. S100 gel was indicated for refinement, and S300 and S500 gels for structure and volume. The doctors evaluated the clinical outcomes of rejuvenation or beautification using the Global Aesthetic Improvement Scale (GAIS), and patient satisfaction using the Likert scale, 1, 3, and 6 months after the procedures. Patients treated included 4 males and 31 females with a mean age of 43.08 years. An average of 6.33 syringes was used. After 30 days, 80% of patients showed excellent or accentuated improvement, with 94.2% satisfaction. After 3 and 6 months, 80% of patients showed excellent or accentuated improvement, which increased their happiness (97%). Immediate common side effects occurred in 17 patients. One patient had a vascular occlusion, which was quickly reverted using hyaluronidase. Most patients had accentuated improvement and great satisfaction. This new cohesive, highly concentrated HA gel promoted a sustained global improvement and patient satisfaction with expected transitory side effects.

**Keywords:** hyaluronic acid; filler; rejuvenation; rheology



**Citation:** Issa, M.C.A.; Fogaça, A.; Palermo, E.; Maluf, L.; Ormiga, P.; Conrado, L.; Barbizan de Moura, L.H. Global Facial Rejuvenation Using a New Cohesive, Highly Concentrated Hyaluronic Acid Filler: A Descriptive Analysis of 35 Cases. *Cosmetics* **2023**, *10*, 105. <https://doi.org/10.3390/cosmetics10040105>

Academic Editors: Mohamad Goldust, George Kroumpouzou and Christophe Hano

Received: 31 May 2023

Accepted: 29 June 2023

Published: 17 July 2023



**Copyright:** © 2023 by the authors. Licensee MDPI, Basel, Switzerland. This article is an open access article distributed under the terms and conditions of the Creative Commons Attribution (CC BY) license (<https://creativecommons.org/licenses/by/4.0/>).

## 1. Introduction

The modern rejuvenation concept is based on a comprehensive approach to the face, which involves knowledge of anatomical changes related to the ageing process and individualities among genders and ethnicities. Nowadays, injectors can presume how patients will age based on their facial shape and familial characteristics, and can delay this process through early interventions. Frequently, treatments using fillers, botulinum toxin, and biostimulating agents and technologies have excellent results; but, undoubtedly, the use of fillers is the most common procedure worldwide.

Injectable fillers are frequently used to structure, volumize, contour, and fill, providing natural, durable, and reversible results [1]. Many different techniques have been described as suitable options for specific facial regions. Moreover, experts continually develop or improve new techniques for more natural results. To reach these significant results, physicians need to develop technical skills and have deep knowledge of facial anatomy, anatomy of the ageing face, facial assessment, and the filler's rheology.

The face is divided into thirds for cosmetic procedures: upper, middle, and lower. Each third has a layered structural arrangement. Despite some exceptions, such as temporal and palpebral regions, there are five layers: skin, subcutaneous layer, superficial musculoaponeurotic system (SMAS), sub aponeurotic layer (ligaments and soft tissue space), deep fascia and periosteum [2]. The layer where filler is applied is related to the filler's properties and facial clinical evaluation.

A young face presents preserved volumes and well-defined contours, and bone structure has a significant role in individual differences. Facial ageing is a biological process that results in structural modifications from the bone to the skin. Some changes include loss of bone support, redistribution or reduction of fat compartments volume, and repositioning of ligaments [2]. Some facial anthropometric measures progressively increase with age, while some regions of the facial skeleton reabsorb. Areas with a strong predisposition for reabsorption include the midface, particularly the maxilla, superomedial, and inferolateral areas of the orbital border, the piriform region, and the anterior portion of the mandible [2].

During facial assessment, doctors evaluate the shape, symmetry, and proportionality of the thirds in front and profile views in static and dynamic positions. Although symmetry is considered a sign of beauty and attractiveness, it is essential to consider other principles, such as balance and harmony; good injectors should know how to use fillers as an ally to perform their art. Although techniques for filling are similar, each patient has a unique face with deficiencies, and needs an individualized diagnosis. The goal is to restore youthfulness without overdoing it, maintaining the main characteristics without caricaturing; filling is not only about rejuvenation, but also facial beautification. In 2021, Ormiga and Issa [3] brought attention to the fact that using golden anthropometric measurements only sometimes helps physicians during cosmetic procedures. Still, the insight gained by using optical illusions facilitates injectors in their facial assessment and filling execution, enabling them to attain good results in their daily routine.

Hyaluronic acid (HA) is a polysaccharide (glycosaminoglycan) that repeats D-glucuronic acid and N-Acetyl-D-glucosamine disaccharide units, and is the most abundant glycosaminoglycan in the extracellular matrix of human tissue [4]. HA gel is the most common filler used worldwide. Its physical and chemical properties vary according to the manufacturing process, and the characteristics of the final product are crucial for its clinical indication [5]. Specific physicochemical properties of HA gel are required to fill, volumize, sustain, and contour different anatomical areas and layers. Ideally, HA gels should have a consistency similar to that of the surrounding tissue to be injected to achieve a natural feel. They must also sustain their shape against the constant physical strain caused by muscle contraction. Generally, softer gels are indicated to fill superficial layers, and are not usually meant to perform lifting or volumizing, for which stiffer gels are proposed [6].

HA gel strength is defined as overall resistance to deformation, which is determined by its rheological properties and the concentration of the gel at maximum swelling. HA exhibits poor biomechanical properties in its natural state, and is rapidly cleared when

injected into normal skin. Chemical modification is required to improve mechanical properties. The addition of crosslinkers creates a three-dimensional network and a firmer gel that can resist degradation. The most common crosslinker molecule is 1,4-Butanediol diglycidyl ether (BDDE). The degrees of chemical modification and natural crosslinking among HA strains are related to the gel's firmness, which determines its elastic modulus ( $G'$ ) [7–9]. The crosslinking reaction results in a gel block, which must be sized to pass through fine-bore needles. Sizing is a process referred to as gel calibration. It can be accomplished by passing the gel mass through a series of sieves. An alternative way to size a large gel mass is to break it down through homogenization [9].

Three main properties determine filler performance under shear and compression/stretching forces: viscoelasticity, viscosity, and cohesivity [7,10]. Viscoelasticity is a property of HA fillers that exhibits viscous and elastic behaviors when undergoing shear deformation. Four rheological parameters describe this property: elastic modulus ( $G'$ ), viscous modulus ( $G''$ ),  $\tan \delta$ , and complex modulus ( $G^*$ ). The  $G'$  measures elastic properties, representing the energy fraction of  $G^*$  stored by the gel and used to recover the original shape. The  $G''$  measures viscous properties, representing the energy fraction of  $G^*$  lost on shear deformation through internal friction. The  $\tan \delta$  measures the ratio between viscous and elastic properties; a lower  $\tan \delta$  is associated with higher elasticity. The  $G^*$  measures overall viscoelasticity or hardness, and represents how difficult it is to alter the shape of the filler [8].

Viscosity measures a filler's resistance to flow when shear stress is applied. It affects the extrusion force. It is related to the degree of crosslinking, the average gel particle size, and the manufacturing process [6]. Cohesivity is the property HA fillers exhibit when undergoing deformation compression/stretching forces. It represents the energy responsible for a relative strength that induces the three-dimensional structure of the HA gel. It depends on the distance between particles and, consequently, on the concentration of the solid immersed in the fluid phase [11]. HA filler with lower cohesivity has weaker adhesion forces, and tends to lose projection easier than a filler with higher cohesivity and equivalent  $G'$ . HA gels are constantly subjected to intrinsic force due to tension and muscle and soft tissue movements above the bone. Therefore, some authors brought attention to the fact that not only the  $G'$  matters; cohesivity is also an essential parameter to predict a gel's behavior after it is implanted into tissue, where it experiences intrinsic and extrinsic forces [8,9,12].

A new Korean homogenous HA gel, called e.p.t.q (epitique), is now available in Brazil. It is a cohesive high-concentrated (24 mg/mL) HA gel with dual (physical and chemical) crosslinking technology and the same particle size in all three presentations (S100, S300, and S500) (data from Jetema Laboratory, Republic of Korea), which vary only in their crosslinking degree (S100 has the lowest  $G'$  and S500 the highest) [13].

Recently, a rheological study [13] conducted in Brazil showed that these three gels were non-Newtonian fluids with pseudoplastic behavior. S500 gel showed the highest  $G'$  and complex modulus, and S100 gel showed the highest  $\tan \delta$  and cohesiveness. S300 gel showed intermediary properties with  $\tan \delta$  and viscosity similar to that of S500 gel. S500 gel, due to its high  $G'$  and low  $\tan \delta$ , is indicated for facial structuring and lifting. In contrast, the low  $G'$  and high  $\tan \delta$  of S100 gel are indicated for refinement. The intermediate values of S300 gel make it suitable for lifting or refinement. The intermediate  $G'$  and high cohesivity of S300 gel were reported by Lee et al. [14] as essential characteristics for filling the frontal region. As different characteristics of fillers enable complementary effects, the association of the three types of e.p.t.q. can promote global facial rejuvenation.

Considering the rheologic properties described above, this study aimed to describe the clinical results, patient satisfaction, and side effects of 35 patients submitted to global facial treatment using these three new fillers.

## 2. Materials and Methods

This is a retrospective descriptive study. The Pro-cardíaco Hospital Ethics Committee approved the study (CEP 5.950.950). Written informed consent was obtained from the patients to publish this paper.

For this study, we analysed the results of global facial treatment in 35 patients selected by seven dermatologists in Brazil. Patients of both sexes desiring beautification or rejuvenation were included; all of them had indications for the filling procedure. Criteria for exclusion were pregnancy and lactation, previous cosmetic procedures or surgery at least one year previous, smokers, collagen autoimmune diseases, past history of complications with cosmetic procedures, past history of permanent filler in the face, active infection, skin cancer, or any other illness that could impair treatment.

Each dermatologist decided the best technique for a given procedure according to the facial assessment. The patient's assessment and the injector's experience defined the number of syringes, the regions to be treated (upper face, midface, and lower face), and the application technique using needles or cannulas (22 G or 25 G), obeying the rheologic properties of the fillers.

Three cohesive HA gel fillers (eptq<sup>®</sup>, Jetema, Wonju-si, Republic of Korea) with 24 mg/mL, the same particle size, and different  $G'$  were used (e.p.t.q. S100, S300, and S500). They had different rheological properties: S500 gel had the highest  $G'$  and complex modulus; S100 gel had the highest  $\tan \delta$  and cohesiveness; and S300 gel had intermediary properties with  $\tan \delta$  and viscosity similar to that of the S500 gel. All three presentations had 1.2 mL in the syringes. The rheologic properties of the fillers determined the injection of S300 and S500 gels for structuring and reshaping (mid-face and lower face), and S100 gel for refinement.

S300 gel was applied using a 22 G cannula in the deep fat compartments of the midface, supraperiosteal in the frontal region, and subcutaneous layer, and using a 25 G cannula in the lips. S500 gel was applied using a 22 G cannula in the subcutaneous superficial layer in the mandibula and mentum, where it was also used in the deep layer. S100 gel was applied in the subcutaneous layer using a 25 G cannula to treat the lips and a 22 G cannula for the perioral area, nasolabial fold, and temporal and mentum areas. In the mentum, it was injected above S500 gel. S100 gel was applied deeply under the orbicularis oculi muscle in the tear trough.

Each dermatologist performed the treatment on five patients and evaluated the clinical outcome of global facial rejuvenation, or beautification in the case of young patients, using the Global Aesthetic Improvement Scale (GAIS). Patients answered the questionnaire about procedure satisfaction using the Likert scale. Both evaluations were performed 1, 3, and 6 months after the procedure. The GAIS classified improvement into five grades: (1) excellent improvement, (2) accentuated improvement, (3) improvement, (4) without improvement, and (5) worse [6]. The Likert scale classified patient satisfaction into five grades: (1) very satisfied, (2) satisfied, (3) neutral, (4) unsatisfied, and (5) very unsatisfied [7].

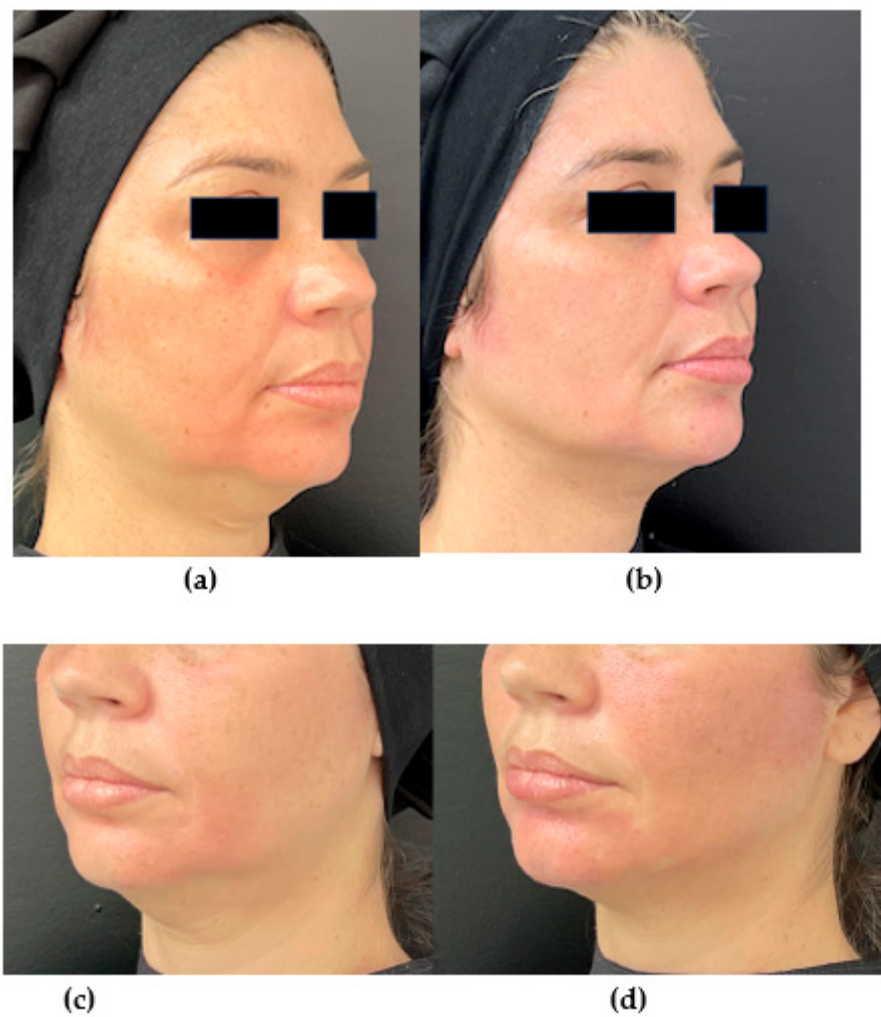Side effects were classified as immediate (just after the procedure), recent (until 48 h after the procedure), and late (after 48 h of the procedure).

## 3. Results

Patients treated included 4 males and 31 females, with a mean age of 43.08 years. An average of 6.33 syringes was used per patient. Clinical evaluation, patient satisfaction before and after 1, 3, and 6 months, and side effects are described below.

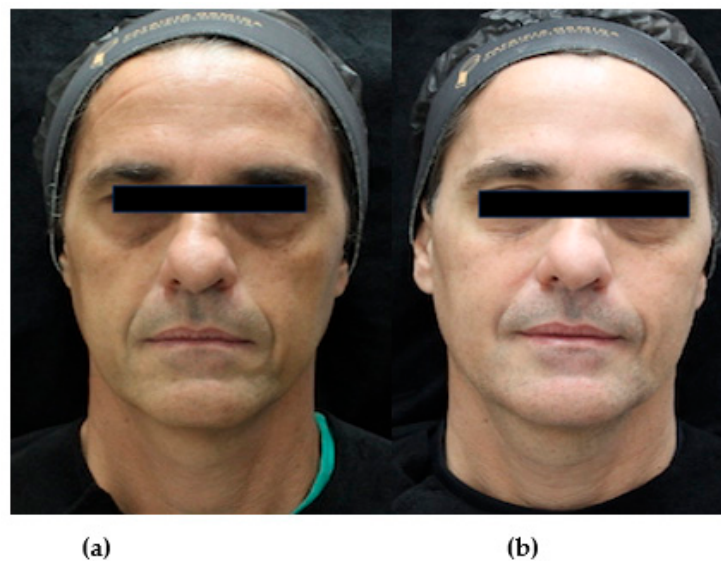### 3.1. Clinical Evaluation (GAIS)

After 1 month, 11 (31.4%) patients showed excellent improvement (Figure 1a–d), 17 (48.5%) had accentuated improvement, and 7 (20%) were classified as improved. Note the excellent improvement of the lid-cheek junction and dark eye circles after malar treatment using S300 gel (Figure 1a,b) and the mandibular line treated using S500 gel (Figure 1a–d).



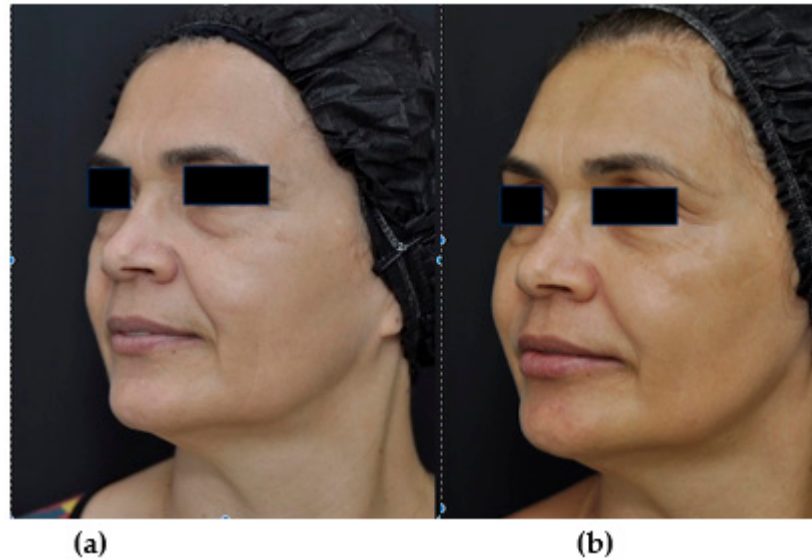
**Figure 1.** (a–d): Excellent improvement: (a,c) before and (b,d) after 1 month of treatment.

After 3 months, 6 patients (17%) showed excellent improvement (Figure 2a,b), 22 (62.8%) had accentuated improvement, 5 (14.2%) were classified as improved, and 2 (5.7%) did not show improvement.

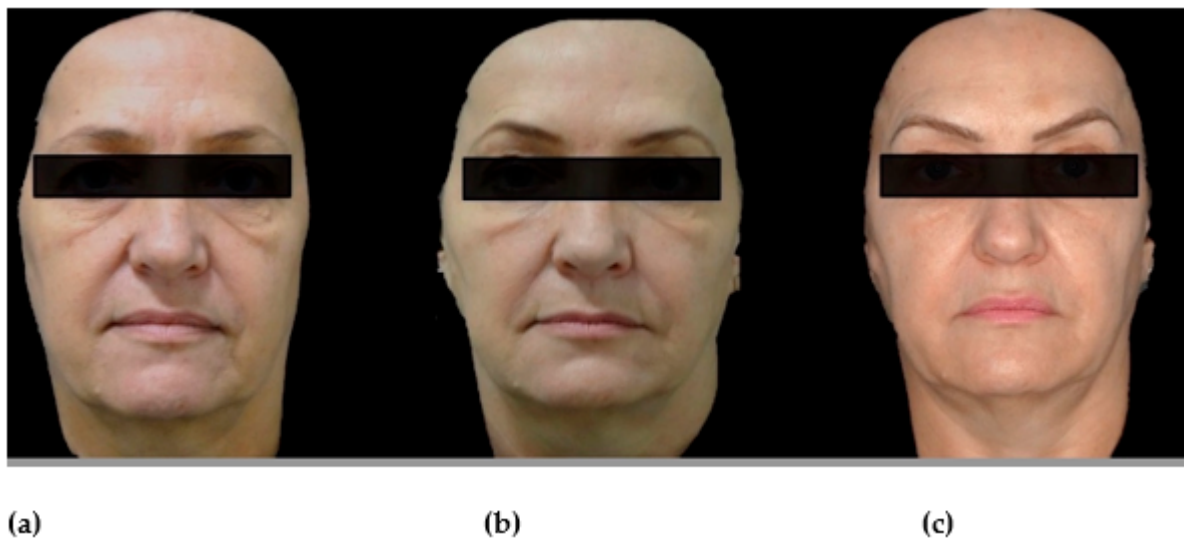


**Figure 2.** (a,b): Excellent improvement: (a) before and (b) after 3 months of treatment.

After 6 months, 6 patients (17%) showed excellent improvement, 22 (62.8%) had accentuated improvement, 4 (11.4%) were classified as improved (Figure 3a,b), and 3 (8.5%) did not show improvement. Some patients improved progressively over time (Figure 4a–c) (Table 1).



**Figure 3.** (a,b): Improvement: (a) before and (b) after 6 months of treatment.



**Figure 4.** (a–c): Progressive improvement: (a) before, (b) after 3 months, and (c) after 6 months of treatment.

**Table 1.** Clinical results after 1, 3, and 6 months according to the GAIS<sup>1</sup>.

Level of Satisfaction	After 1 Month	After 3 Months	After 6 Months
Very Satisfied	18	17	16
Satisfied	15	17	18
Neutral	2	1	1
Unsatisfied	0	0	0
Very Much Unsatisfied	0	0	0

<sup>1</sup> The Global Aesthetic Improvement Scale.

### 3.2. Patients' Satisfaction

After 1 month, 18 (51.4%) patients were very satisfied, 15 (42.8%) were satisfied, and 2 (5.7%) were neutral. After 3 months, 17 (48.5%) patients were very satisfied, 17 (48.5%) were satisfied, and 1 (2.8%) had no opinion.

After 6 months, 16 (45.7%) patients were very satisfied, 18 (51.4) were satisfied, and 1 (2.8%) had no opinion (Table 2).

**Table 2.** Subjective impression of the treatment according to the Likert scale over time.

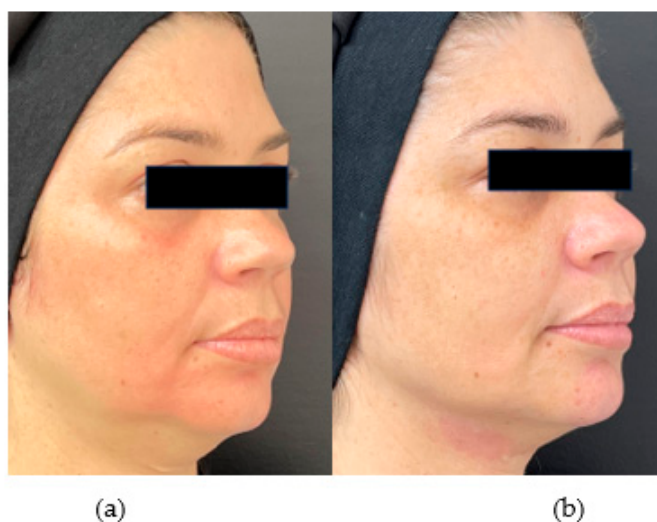
Degree of Improvement	After 1 Month	After 3 Months	After 6 Months
Excellent Improvement	11	6	6
Accentuated Improvement	17	22	22
Improvement	7	5	4
Without Improvement	0	2	3
Worse	0	0	0

### 3.3. Side Effects

Common immediate and transitory side effects, including local pain, ecchymosis, oedema, and erythema, occurred in 17 patients, with complete recovery without intervention. One patient presented signs of vascular occlusion within 24 h in the mentum area despite using a cannula. In this case, intervention was indicated, and the patient presented complete recovery after 1500 UI of hyaluronidase injection.

## 4. Discussion

Many authors report the efficacy of fillers in promoting global facial rejuvenation using different types of HA gel, and this study corroborates this concept. Here, most patients had accentuated improvement with great satisfaction at 1, 3, and 6 months after treatment, despite different techniques, patients' ages, and clinical assessments. Improvements could be observed after the first month and were sustained during follow-up (Figure 5a,b). The combination of three fillers, used according to their physicochemical properties, enabled these results. In this study, the physicians used the softest gel (S100 gel) to treat the perioral region, lips, palpebromalar groove, and temporal region. The strongest gel (S500 gel) was used to treat the lower face, mentum and mandible, and the middle face in some cases. The gel with intermediate rheological properties was mainly used in the middle face, but also in the lips. It is important to highlight the cohesivity of these gels, which is an essential characteristic for filling regions where gel integration is crucial for attaining good results and avoiding side effects, as reported by Lee et al. [14].



**Figure 5.** (a,b): Sustained improvement after 6 months: (a) before and (b) after 6 months.

Sustained improvement after HA filling has already been reported, and can be explained not only by the maintenance of the product in the skin, but also by the skin remodeling induced by its presence [15].

The average of products (4–9 syringes) used for global facial treatments in this study was similar or fewer to the number of fillers used in other studies described in the literature [16]. This finding could be related to gel properties, including high HA concentration and cohesiveness, which are associated with a suitable lifting capacity of the gel [6,13,14].

Side effects were similar to those described as possible in the literature [17].

## 5. Conclusions

Based on this study's data analysis, the combination of three new cohesive and highly concentrated HA fillers (e.p.t.q. S100, S300, and S500 gels) provided accentuated and sustained global facial improvements over the follow-up period, with excellent patient satisfaction and expected temporary side effects. These new products are suitable and effective fillers for injectors to promote facial beautification and rejuvenation, as they possess essential physicochemical properties for structuring, volumizing, and lifting.

**Author Contributions:** M.C.A.I. was responsible for the literature review, writing, reviewing, and editing. A.F. and E.P. worked on the literature review and project administration. L.M. was responsible for data curation and analysis. L.C. and P.O. were responsible for the draft preparation. L.H.B.d.M. was responsible for editing and reviewing. All authors have read and agreed to the published version of the manuscript.

**Funding:** This research received no external funding.

**Institutional Review Board Statement:** This study was conducted in accordance with the Declaration of Helsinki and approved by the Institutional Review Board, Pro-cardíaco Hospital Ethics Committee (CEP 5.950.950).

**Informed Consent Statement:** Written informed consent was obtained from the patients to publish this paper.

**Data Availability Statement:** Data are available from the corresponding author upon reasonable request.

**Acknowledgments:** We thank Medbeauty for donating HA gel filler for the procedures.

**Conflicts of Interest:** The authors participate in the Advisory Board for Medbeauty. Andreia Fogaça, Eliandre Palermo, Maria Claudia Issa, Luciana Maluf, and Luis Moura are Medbeauty spokespersons. They managed the donation of fillers for this study, but none of them were sponsored to participate in this specific study.

## References

1. Fitzgerald, R.; Carqueville, J.; Yang, P.T. An approach to structural facial rejuvenation with fillers in women. *Int. J. Womens Dermatol.* **2019**, *5*, 52–67. [[CrossRef](#)] [[PubMed](#)]
2. Mendelson, B.C.; Jacobson, S.R. Surgical anatomy of the midcheek: Facial layers, spaces, and the midcheek segments. *Clin. Plast. Surg.* **2008**, *35*, 395–404, discussion 393. [[CrossRef](#)] [[PubMed](#)]
3. Ormiga, P.; Issa, M.C.A. How optical illusions can help during filler procedures for facial beautification. *J. Cosmet. Dermatol.* **2022**, *21*, 2684–2685. [[CrossRef](#)] [[PubMed](#)]
4. Pierre, S.; Liew, S.; Bernardin, A. Basics of dermal filler rheology. *Dermatol. Surg.* **2015**, *41* (Suppl. S1), S120–S126. [[CrossRef](#)] [[PubMed](#)]
5. Choi, M.S. Basic rheology of dermal filler. *Arch Plast. Surg.* **2020**, *47*, 301–304. [[CrossRef](#)] [[PubMed](#)]
6. Carruthers, J.; Carruthers, A.; Humphrey, S. Introduction to Fillers. *Plast. Reconstr. Surg.* **2015**, *136*, 120S–131S. [[CrossRef](#)] [[PubMed](#)]
7. Edsman, K.; Nord, L.I.; Ohrlund, A.; Lärkner, H.; Kenne, A.H. Gel properties of hyaluronic acid dermal fillers. *Dermatol. Surg.* **2012**, *38 Pt 2*, 1170–1179. [[CrossRef](#)] [[PubMed](#)]
8. Fagien, S.; Bertucci, V.; von Grote, E.; Mashburn, J.H. Rheologic and Physicochemical Properties Used to Differentiate Injectable Hyaluronic Acid Filler Products. *Plast. Reconstr. Surg.* **2019**, *143*, 707e–720e. [[CrossRef](#)] [[PubMed](#)]
9. Kablik, J.; Monheit, G.D.; Yu, L.; Chang, G.; Gershkovich, J. Comparative physical properties of hyaluronic acid dermal fillers. *Dermatol. Surg.* **2009**, *35* (Suppl. S1), 302–312. [[CrossRef](#)] [[PubMed](#)]
10. Heitmiller, K.; Ring, C.; Saedi, N. Rheologic properties of soft tissue fillers and implications for clinical use. *J. Cosmet. Dermatol.* **2021**, *20*, 28–34. [[CrossRef](#)] [[PubMed](#)]



11. Faivre, J.; Gallet, M.; Tremblais, E.; Trévidic, P.; Bourdon, F. Advanced Concepts in Rheology for the Evaluation of Hyaluronic Acid-Based Soft Tissue Fillers. *Dermatol. Surg.* **2021**, *47*, e159–e167. [[CrossRef](#)] [[PubMed](#)]
12. Lee, W.; Hwang, S.G.; Oh, W.; Kim, C.Y.; Lee, J.L.; Yang, E.J. Practical Guidelines for Hyaluronic Acid Soft-Tissue Filler Use in Facial Rejuvenation. *Dermatol. Surg.* **2020**, *46*, 41–49. [[CrossRef](#)] [[PubMed](#)]
13. Issa, M.C.; Fogaca, A.; Palermo, E.; Fontes, M.; Barud, H.S.; Dametto, A.C. A New Cohesive High-Concentrated Hyaluronic Acid Gel Filler: Correlation between Rheologic Properties and Clinical Indications. *J. Biomed. Res. Environ. Sci.* **2023**, *4*, 614–618. [[CrossRef](#)]
14. Lee, W.; Yoon, J.-H.; Koh, I.-S.; Oh, W.; Kim, K.-W.; Yang, E.-J. Clinical application of a new hyaluronic acid filler based on its rheological properties and the anatomical site of injection. *Biomed. Dermatol.* **2018**, *2*, 22. [[CrossRef](#)]
15. França Wanick, F.B.; Almeida Issa, M.C.; Luiz, R.R.; Soares Filho, P.J.; Olej, B. Skin Remodeling Using Hyaluronic Acid Filler Injections in Photo-Aged Faces. *Dermatol. Surg.* **2016**, *42*, 352–359. [[CrossRef](#)] [[PubMed](#)]
16. Bertossi, D.; Nocini, P.F.; Rahman, E.; Heydenrych, I.; Kapoor, K.M.; de Maio, M. Non surgical facial reshaping using MD Codes. *J. Cosmet. Dermatol.* **2020**, *19*, 2219–2228. [[CrossRef](#)] [[PubMed](#)]
17. Delorenzi, C. Complications of injectable fillers, part I. *Aesthet. Surg. J.* **2013**, *33*, 561–575. [[CrossRef](#)] [[PubMed](#)]

**Disclaimer/Publisher’s Note:** The statements, opinions and data contained in all publications are solely those of the individual author(s) and contributor(s) and not of MDPI and/or the editor(s). MDPI and/or the editor(s) disclaim responsibility for any injury to people or property resulting from any ideas, methods, instructions or products referred to in the content.

